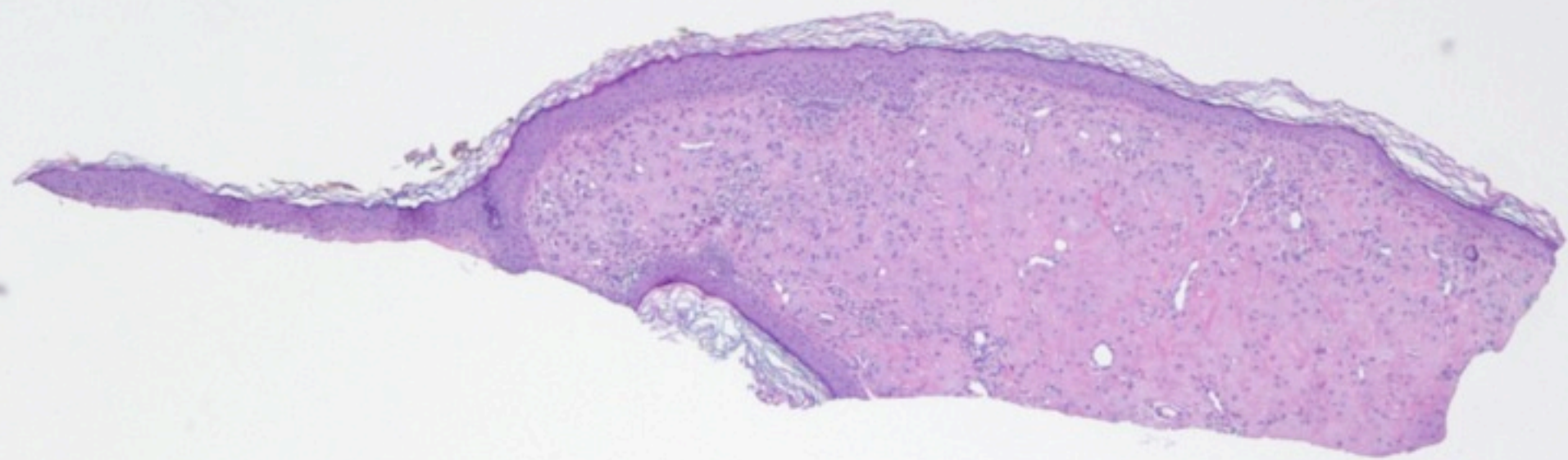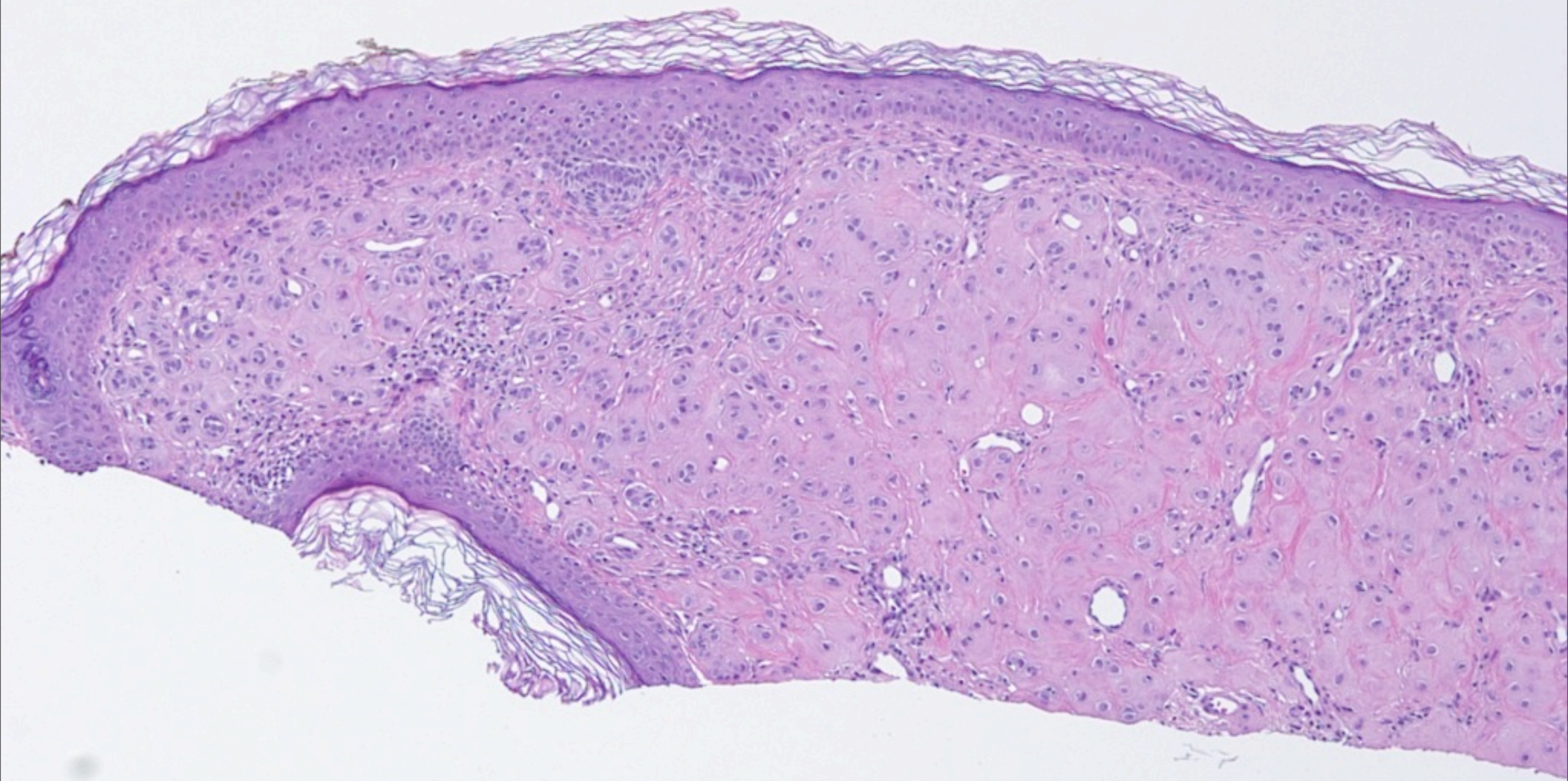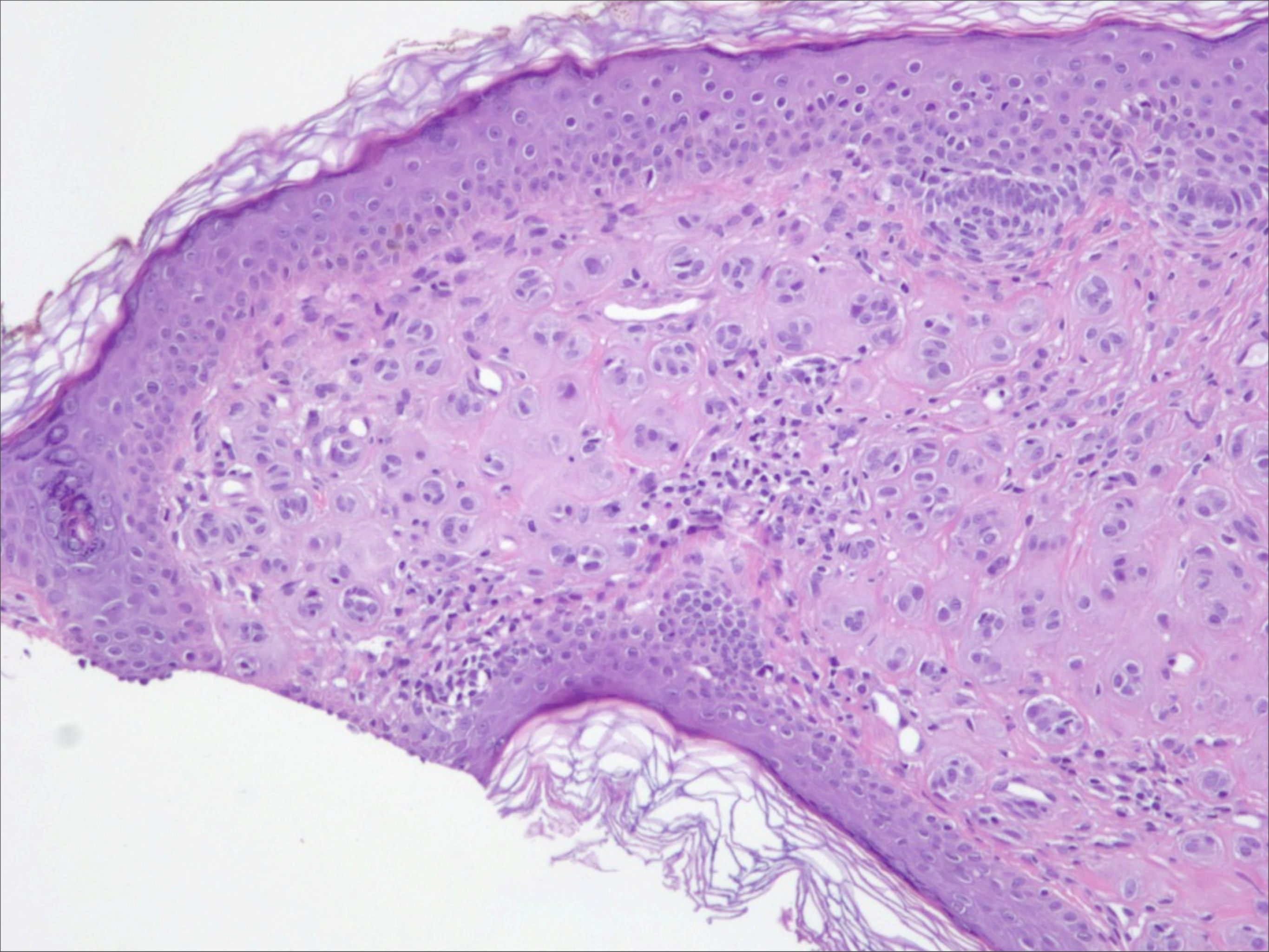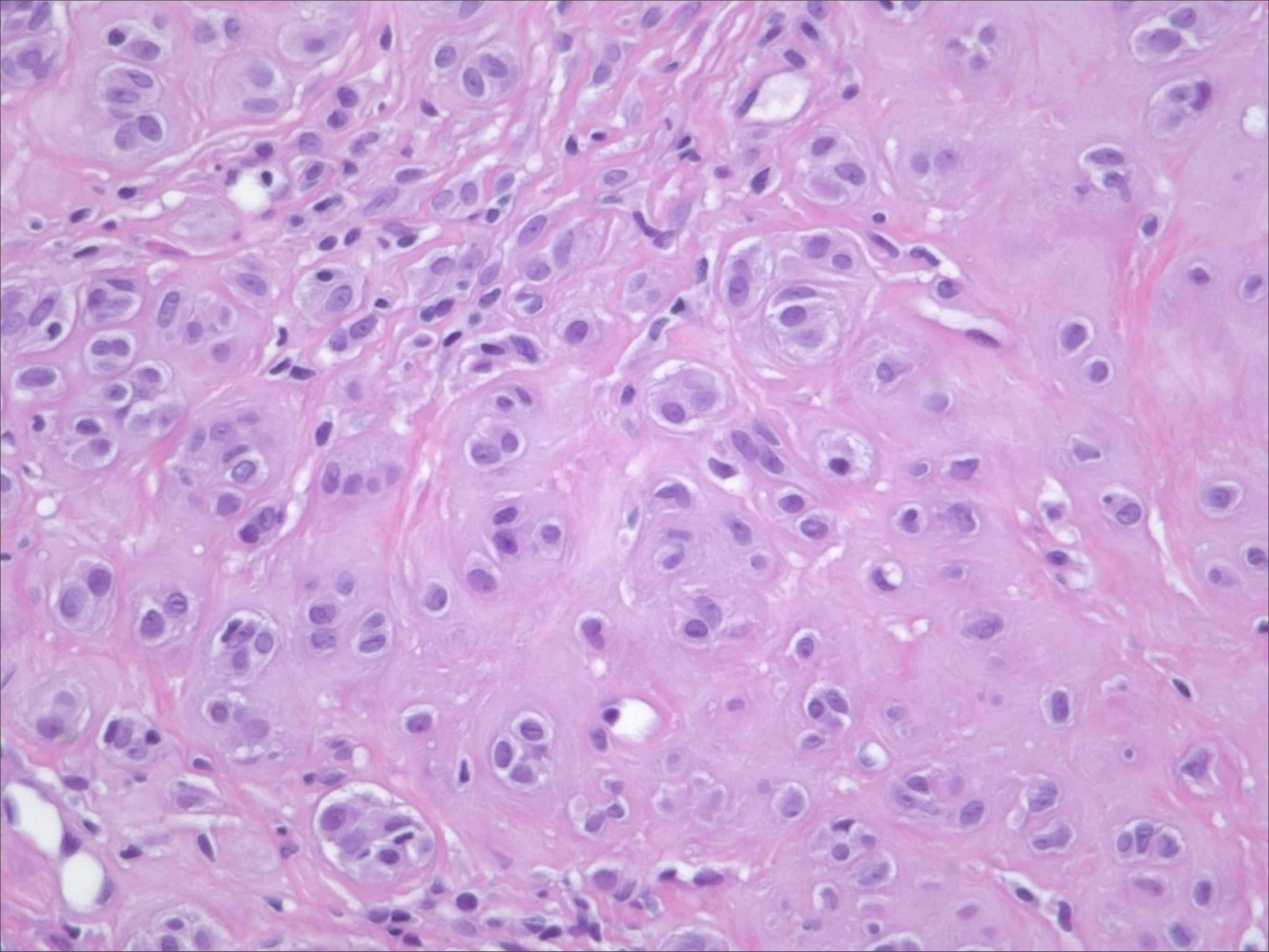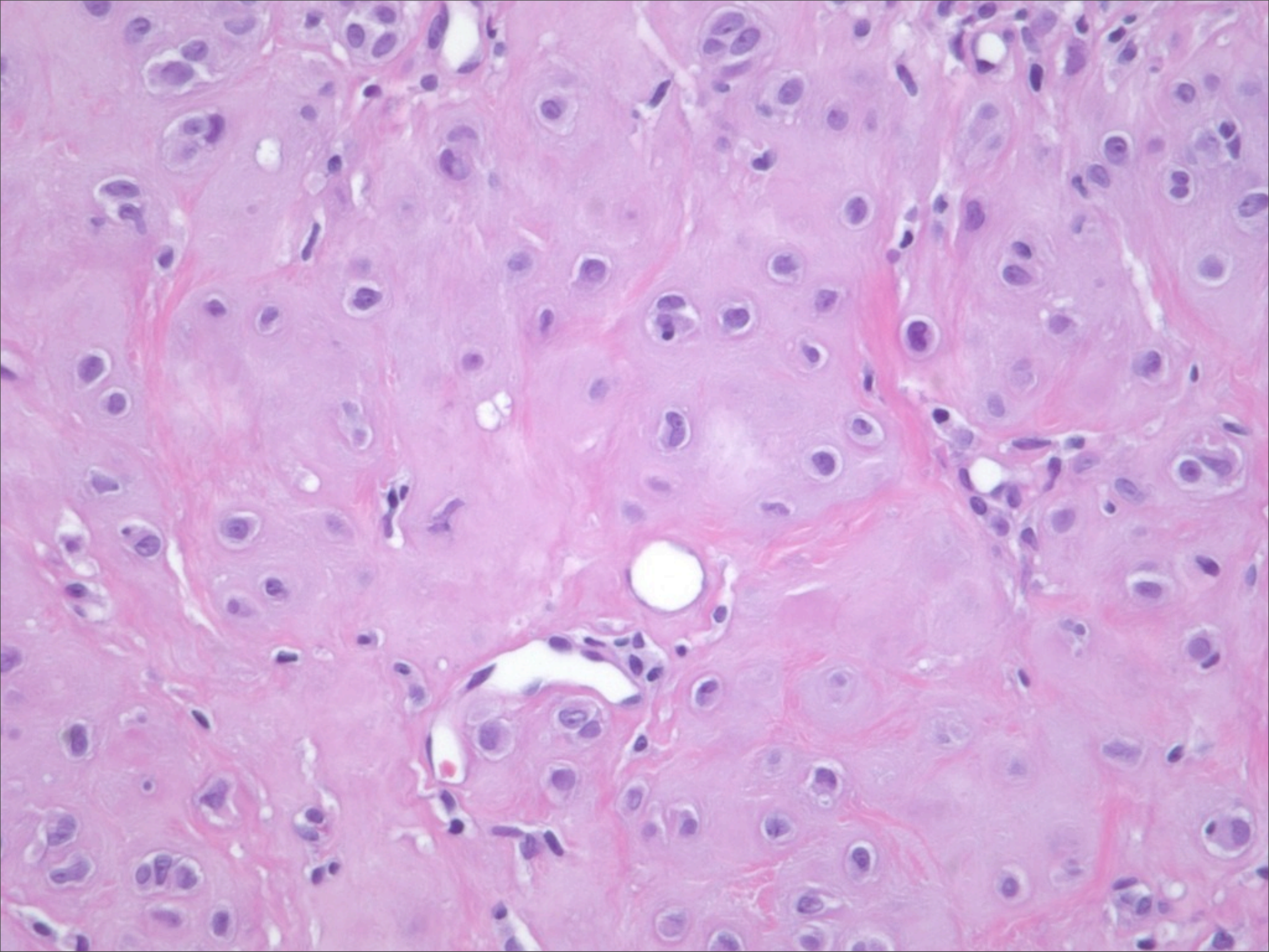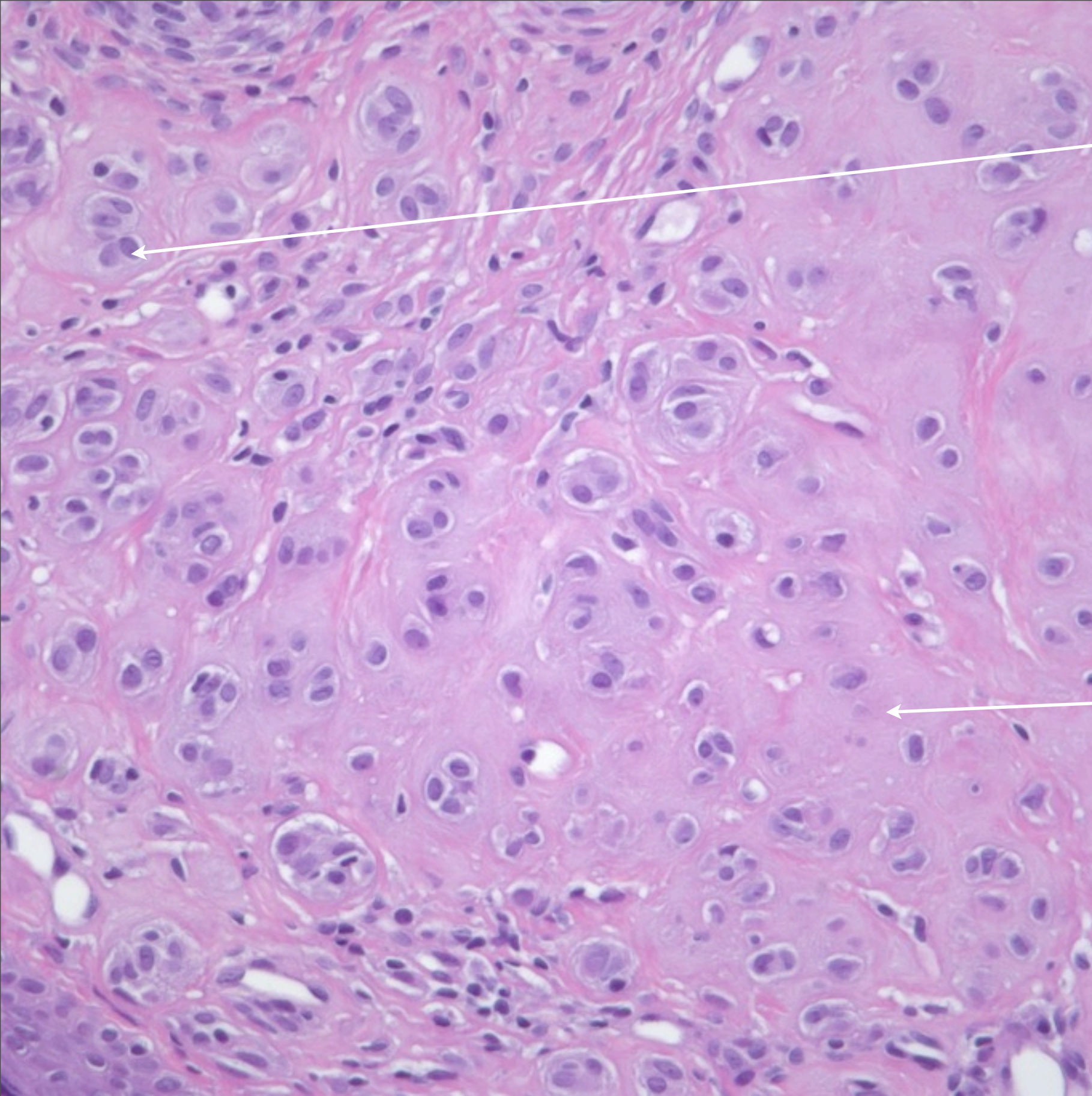


Melanocytic Nevus with Cartilaginous Metaplasia

Notes

- Melanocytic nevi may exhibit a variety of metaplastic changes including:
 - Cartilage, granular cell changes, fat, neural, and bone



Melanocytic Nests

Cartilage